Safety and Utility of Osteopathic Manipulative Treatment for the Acute Care of Severe Traumatic Brain Injury - a Case Report

St. Barnabas Hospital BRONX

NYIT College of Osteopathic Medicine

Adrienne McCallister DO PGY-3, Christopher Brown DO, Michael Smith DO PGY-4, Hugh Ettlinger DO FAAO and Gerard A. Baltazar DO FACOS

NMM/OMM and Surgery Departments, St. Barnabas Hospital, Bronx, NY

INTRODUCTION

The CDC estimates that 1.4 million people sustain traumatic brain injury (TBI) annually of whom 235,000 are hospitalized and 50,000 die.[1] The total number of TBIs has increased by 58% over the past decade, resulting in steadily increasing healthcare expenditures.[2] A multidisciplinary approach is recommended for treatment and rehabilitation after TBI, although the most effective modalities or combination of modalities have yet to be determined.[3,4]

OMT, especially Osteopathy performed in the cranial field may alter CNS physiology[5-9] and has demonstrated significant clinical effects in various populations.[10-14] Historically, acute TBI has been regarded as a potential contraindication to OMT;[15] thus, data regarding the benefits of OMT for acute TBI are sparse.[16] Herein, we describe a case of severe TBI for which OMT was a consistent part of comprehensive, acute inpatient, multimodal care.

CASE DESCRIPTION

History of Present Illness:

H.F. is a 21 year-old male who presented as a level one trauma after a four-story fall. Post-resuscitation Glasgow coma score (GCS) was 7. CT of the brain revealed a R epidural hematomas, R subdural hematoma, bilateral intraparenchymal hematoma as well as diffuse cerebral edema and pneumocephalus (Figure 1).

Craniofacial fractures included LeFort II and III, left temporal bone, left frontal sinus and left orbital roof with suspicion of left optic nerve transection (Figure 2). Extracranial fractures included left C6-7 transverse process and right clavicle fractures. Apart from assorted external soft tissue injuries, other clinical and imaging findings were atraumatic.

In the surgical intensive care unit, the patient remained intubated and was started on hypertonic saline infusion. OMM/NMM consultation and treatment began on hospital day (HD) four. Past medical and surgical history and review of systems were unobtainable at the time of consultation.

Physical exam:

Vitals: T 97.9, HR 80, BP 115/50, RR 18, SpO2 100%
General: intubated, off sedation at the time of exam
Eyes: ice packs placed over eyes with significant periorbital ecchymosis L greater than R with L eye proptosis
Throat: ET tube in place, OG salem sump in place
Neck: cervical collar in place, L subclavian line present
Lungs: mechanical breath sounds on auscultation without rales, rhonchi, wheezes. Ventilator settings: Volume A/C, 40%, 18, 500, +5
Cardiovascular: RRR, no murmurs, rubs or gallops appreciated
Abdomen: soft, bowel sounds present
Genital/Urinary: foley draining clear urine to gravity
Neuro: GCS 6T with non-purposeful limb movements

Osteopathic Structural Exam

Head: OA FSrRl, R>L occipital condylar compression, SBS compression, B/L frontal bones IR, L zygoma IR, L maxilla IR, L temporal bone IR
Cervical: unable to examine as cervical collar in place
Thoracic: Globally decreased excursion of L hemithorax, T2-7 FSRr
Lumbar: L5 FSRl with diminished lumbosacral excursion with thoracic respiration
Sacrum: Sacral base posterior, L sacroiliac joint restriction to lateral distraction
Pelvis: L innominate posterior
LE: L hip ER
UE: R clavicle retracted and abducted with palpable deformity
Ribs: L 3-6 anterior and exhaled
Abdomen: L hemidiaphragm exhaled

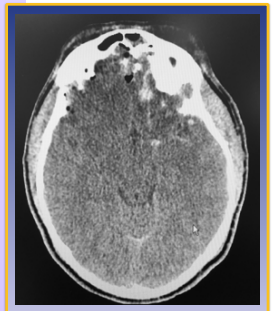

Figure 1: Axial CT brain, demonstrating pneumocephalus and multicompartmental hematomas after severe TBI.

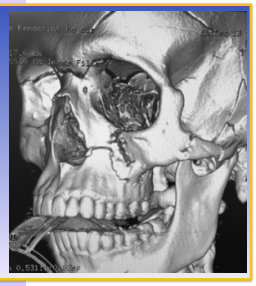

Figure 2: Three-dimensional reconstructed figure, demonstrating LeFort II and III facial fractures.

Assessment and Plan

21 yo M with no known PMHx s/p fall from 4 stories with multicompartmental hematomas, diffuse cerebral edema, Le Fort II and III facial fractures with suspicion for L optic nerve transection, cervical transverse process and R clavicular fractures currently on hypertonic saline, intubated with GCS 6T off sedation with above noted severe acute somatic dysfunction in a traumatic pattern. Gentle OMT was applied to all above-noted areas of somatic dysfunction using balanced membranous and ligamentous tension, myofascial release and osteopathy in the cranial field technique to reduce the traumatic strain pattern, optimize respiratory mechanics and circulation and to promote lymphatic and venous sinus drainage. Patient tolerated treatment without observed complications.

Hospital and Treatment Course

Neurologically, by HD seven, the patient had improved to GCS 11T. By HD 28, he became verbal, and by HD 31, he became fluent with speech. OMT continued throughout his recovery, and the patient received a total of 24 OMT sessions during his 42-day hospital stay.

Hospital and Treatment Course (*continued*)

He was discharged home with GCS 15. There were no adverse outcomes associated with OMT. One month after discharge, repeat cranial imaging demonstrated resolution of all intracranial bleeding and patent ventricles (Figure 3).

During the patient's hospital course, the severity of asymmetry and restricted range of motion of the cranial base, spine and ribs gradually improved. Although still slightly asymmetric at the time of discharge, there was improvement in the overall positional symmetry of the facial bones.

Figure 3: Axial CT brain one month after discharge showing resolution of intracranial bleeding and patent ventricles

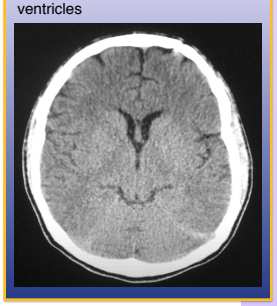

DISCUSSION

TBI is associated with increases in inflammatory cytokines, such as interleukin (IL)-2, IL-6 and tumor necrosis factor-alpha (TNF-a), requiring removal via venous and lymphatic drainage systems.[17] 95% of the blood flowing through the dural venous sinuses leaves the head through the jugular foramina, with the remaining 5% draining via facial veins and the external jugular vein.[18] However, following TBI, magnetic resonance venography has demonstrated decreased venous outflow through these primary channels and greater use of secondary pathways.[17] This favoring of venous drainage outside the jugular system is associated with increased intracranial pressure (ICP) and decreased intracranial compliance.[17,19]

The dural venous sinuses are located in the bifurcated attachment of the dural membranes between the periosteal and meningeal layers; therefore, derangements in the tension of the dural membranes may result in derangements of venous sinus structure and suboptimal drainage.[20,21] The tentorium cerebelli attach to the superior border of the petrous portion of the temporal bones, enclosing the superior petrosal sinuses. Posteriorly, they attach to the transverse ridge on the inner surface of the occipital bone, encasing the transverse sinuses.[22] The falx cerebri attaches anteriorly along the frontal crest of the frontal bone and onto the crista galli of the ethmoid, and posteriorly, attaches to the upper aspect of the tentorium

Discussion (*continued*)

where it houses the superior and inferior sagittal sinuses.[22] Even slight displacement of the temporal bones, occiput or frontal bones can alter tensions through this dural system, causing the open oval shape of the lumen of the dural venous sinuses to narrow.[23]

Recent research has identified functioning lymphatic vessels running parallel to the dural venous sinuses—these lymphatic vessels carry immune cells and fluid from the cerebrospinal fluid (CSF).[24] These vessels may act as the link between the intraparenchymal glymphatic and the extracranial lymphatic systems.[24] Authors recently described this glymphatic system as a brain-wide paravascular pathway for CSF and interstitial fluid (ISF) exchange that facilitates the clearance of solutes and waste from the brain.[25]

OMT has been shown to increase flow through the lymph system[26-30] and therefore may play a role in the treatment of post-traumatic lymphatic drainage and clearance of inflammatory products and damaged tissues. Other data show that extracranial lymphatic techniques may improve the efficacy of the immune system.[31,32] In this case study, we observed somatic dysfunction of the cranial bones improving during acute care management, resulting in more symmetry and greater range of motion of the cranial bones and membranes which house the venous sinus and cranial lymphatic systems.

REFERENCES

[1] Langlois, JA, Rutland-Brown W, Thomas KE. 2010. Traumatic Brain Injury in the United States: Emergency Department Visits, Hospitalizations, and Deaths. Atlanta: Centers for Disease Control and Prevention, National Center for Injury Prevention and Control; 2006. [Cited 2015, Nov 4]; Available from: http://www.cdc.gov/traumaticbraininjury/pdf/blue_book.pdf.
[2] Centers for Disease Control and Prevention [Internet]. Rates of TBI-related Emergency Department Visits, Hospitalizations, and Deaths — United States, 2001–2010. Atlanta, GA: 2014, Feb 24 - [cited 2015 Nov 4]; Available from: http://www.cdc.gov/traumaticbraininjury/data/rates.html.
[3] Brasure M, Lamberty GJ, Sayer NA, Nelson NW, Macdonald R, Ouellette J, Wilt TJ. Participation after multidisciplinary rehabilitation for moderate to severe traumatic brain injury in adults: a systematic review. Arch Phys Med Rehabil. 2013 Jul;94(7):1398-420. doi: 10.1016/j.apmr.2012.12.019. Epub 2013 Jan 21.
[4] Brasure M, Lamberty GJ, Sayer NA, Nelson NW, MacDonald R, Ouellette J, Tacklind J, Grove M, Rutks IR, Butler ME, Kane RL, Wilt TJ (Agency for Healthcare Research and Quality). 2012. Multidisciplinary Postacute Rehabilitation for Moderate to Severe Traumatic Brain Injury in Adults (Report No.: 12-EHC101-EF). [Cited 2015, Nov 4]; Available from: http://effectivehealthcare.ahrq.gov/ehc/products/283/1160/CER72_TBIPostacuteRehab_Execsumm_20120625.pdf.
[5] Cutler MJ, Holland BS, Stupski BA, Gamber RG and Smith ML. Cranial manipulation can alter sleep latency and sympathetic nerve activity in humans: a pilot study. *J Altern Complement Med.* 2005 Feb;11(1):103.
[6] Milnes K and Moran RW. Physiological effects of a CV4 cranial osteopathic technique on autonomic nervous system function: A preliminary investigation. *Int J Osteopath Med.* 2007 10(1):8-17.
[7] Sandhouse ME, Shechtman OD, Sorkin R, Drowos JL, Caban-Martinez AJ, Patterson, MM. Shallo-Hoffmann J, Hardigan P and Snyder A. Effect of Osteopathy in the Cranial Field on Visual Function—A Pilot Study. *J Am Osteopath Assoc.* 2010 110: 4, April; 239-240.
[8] Shi X, Rehrer S, Prajapati P, Stoll ST, Gamber RG and Downey HF. Effect of cranial osteopathic manipulative medicine on cerebral tissue oxygenation. *J Am Osteopath Assoc.* 2011 Dec;111(12):660-6.
[9] Miana L, Bastos VH, Machado S, Arias-Carrión O, Nardi AE, Almeida L, Ribeiro P, Machado D, King H and Silva JG. Changes in alpha band activity associated with application of the compression of fourth ventricular (CV-4) osteopathic procedure: a qEEG pilot study. *J Bodyw Mov Ther.* 2013 Jul;17(3):291-6.
[10] Mills MV, Henley CE, Barnes LL, Carreiro JE and Degenhardt BF. The use of osteopathic manipulative treatment as adjuvant therapy in children with recurrent acute otitis media. *Arch Pediatr Adolesc Med.* 2003 Sep;157(9):861-6.
[11] Jäkel A and von Hauenschild P. Therapeutic effects of cranial osteopathic manipulative medicine: a systematic review. *J Am Osteopath Assoc.* 2011 Dec;111(12):685-93.
[12] Lessard S, Gagnon I and Trottier N. Exploring the impact of osteopathic treatment on cranial asymmetries associated with nonsynostotic plagiocephaly in infants. *Complement Ther Clin Pract.* 2011 Nov;17(4):193-8.
[13] Lopez D, King HH, Knebl JA, Kosmopoulos V, Collins D and Patterson RM. Effects of comprehensive osteopathic manipulative treatment on balance in elderly patients: a pilot study. *J Am Osteopath Assoc.* 2011 Jun;111(6):382-8.
[14] Müller T and Pietsch A. Comparison of gait training versus cranial osteopathy in patients with Parkinson's disease: a pilot study. *Neuro Rehabilitation.* 2013 32(1):135-40.
[15] DeStefano, L. Craniosacral technique. In: Greenman's Principles of Manual Medicine, 4th Ed. Philadelphia, PA: Lippincott Williams and Wilkins; 2011.
[16] King HH. Support for Application of Cranial Osteopathic Manipulative Medicine in Patients With PTSD and TBI. *J Am Osteopath Assoc.* 2015 Jul;115(7):464. doi: 10.7556/jaoa.2015.098.
[17] Pomschar A. MRI evidence for altered venous drainage and intracranial compliance in mild traumatic brain injury. *Plos One.* 2013;8(2):1-9.
[18] Ettinger H, Gintis B. Osteopathy in the cranial field. In: DiGiovanna EL, Schiowitz S, Dowling DJ, editors. An Osteopathic Approach to Diagnosis and Treatment, 3rd Ed. Philadelphia, PA: Lippincott Williams and Wilkins; 2005. p 109-112.
[19] Tain RW, Alperin N. Noninvasive intracranial compliance from MRI-based measurements of transcranial blood and CSF flows: indirect versus direct approach. *IEEE Trans Biomed Eng.* 2009 Mar;56(3):544-51.
[20] Nelson KE, Sergueef N, Glonek T. Cranial manipulation induces sequential changes in blood flow velocity on demand. *Am Acad Osteopath J.* 2004;14(3):15-17.
[21] Nelson KE, Sergueef N, Glonek T. The effect of an alternative medical procedure upon low-frequency oscillation in cutaneous blood flow velocity. *J Manipulative Physiol Ther.* 2006;29:626-36.
[22] Warwick R, Williams PL. Gray's Anatomy 35th British Edition. Philadelphia, PA: W.B. Saunders Company; 1973.
[23] Magoun, HI, ed. Osteopathy in the Cranial Field, 3rd Ed. Fort Worth, TX: Sutherland Cranial Teaching Foundation;1976.
[24] Louveau A, Smirnov I, Keyes TJ, Eccles JD, Rouhani SJ, J. Peske D, Derecki NC, Castle D, Mandell JW, Lee KS, Harris TH, Kipnis J. Structural and functional features of central nervous system lymphatic vessels. *Nature.* 2015;523(7560):337-41.
[25] Iliff J. Is there a cerebral lymphatic system? *Stroke.* 2013 June;44(6 0 1):S93-S95.
[26] Knott EM, Tune JD, Stoll ST and Downey HF. "Increase lymphatic flow in the thoracic duct during manipulative intervention." *J Am Osteopath Assoc.* 2005;105(10):447-56.
[27] Prajapati P, Shah P, King HH et al. "Lymphatic pump treatment increases thoracic duct lymph flow in conscious dogs with edema due to constriction of the inferior vena cava." *Lymphat Res Biol.* 2010;8(3):149-54.
[28] Schander A, Downey HF and Hodge LM. "Lymphatic pump manipulation mobilizes inflammatory mediators into lymphatic circulation." *Exp Biol Med.* 2012;237(1):58-63.
[29] Chikly B and Quaghebeur J. "Reassessing cerebrospinal fluid hydrodynamics: a literature review presenting a novel hypothesis for CSF physiology." *J Bodyw Mov Ther.* 2013;17(3):344-54.
[30] Schander A, Padro D, King HH et al. "Lymphatic pump treatment repeatedly enhances the lymphatic and immune systems." *Lymphat Res Biol.* 2013;11(4):219-26.
[31] Jackson KM, Steele TF, Dugan EP et al. "Effect of lymphatic and splenic pump techniques on the antibody response to hepatitis B vaccine: a pilot study." *J Am Osteopath Assoc.* 1998;98(3):155-60.
[32] Paul RT, Stomel RJ, Broniak FF and Williams BB Jr. "Interferon levels in human subjects throughout a 24-hour period following thoracic lymphatic pump manipulation." *J Am Osteopath Assoc.* 1986;86(2):92-5.

St. Barnabas Hospital IRB Approved: 2015.83